

Proceedings of the 56th Annual Convention of the American Association of Equine Practitioners - AAEP -

December 4-8, 2010
Baltimore, Maryland, USA



Next Meeting :

Nov. 18-22, 2011 - San Antonio, Texas, USA



How to Ultrasound the Equine Larynx

Katherine S. Garrett, DVM

Author's address: Rood and Riddle Equine Hospital, PO Box 12070, Lexington, Kentucky 40580-2070; e-mail: kgarrett@roodandriddle.com. © 2010 AAEP.

1. Introduction

Abnormalities of the upper airway (UA) are frequently implicated as a cause of poor performance, exercise intolerance, or abnormal respiratory noise in the equine.¹⁻³ Common abnormalities involving the function of the arytenoid cartilages include recurrent laryngeal neuropathy, arytenoid chondritis, and laryngeal dysplasia. Dorsal displacement of the soft palate (DDSP) and pharyngeal collapse affect the pharyngeal region. Congenital abnormalities and dynamic larynx collapse associated with poll flexion can affect multiple regions of the larynx and pharynx.

Resting UA endoscopy is widely available and is often the first diagnostic tool used in evaluation of UA abnormalities. In many cases, resting endoscopy is sufficient for diagnosis. However, dynamic evaluation, either using a treadmill or a portable over ground videoendoscopy system, is considered to provide a more accurate diagnosis than resting endoscopy.⁴⁻⁶ Unfortunately, dynamic UA examination requires specialized equipment that may not be available locally, may be cost prohibitive for some clients, and may not be appropriate for some horses. Additionally, some UA abnormalities cannot be fully assessed using UA endoscopy.

Laryngeal ultrasonography, first described by Chalmers et al. in 2006,⁷ is a relatively new addition to the diagnostic repertoire for UA disorders. It has proven to be useful clinically in the diagnosis of

many conditions of the UA, especially disorders resulting in abnormal arytenoid movement including recurrent laryngeal neuropathy, arytenoid chondritis, and laryngeal dysplasia, a congenital malformation of the larynx.⁷⁻¹⁰ Laryngeal ultrasonography can be especially helpful in cases where a dynamic examination cannot be performed.

An appreciation of the pathologic changes that occur in diseases of the UA is helpful in understanding the ultrasonographic changes that accompany each disease. Recurrent laryngeal neuropathy results in denervation atrophy and subsequent loss of function of the intrinsic laryngeal muscles innervated by the recurrent laryngeal nerve, including the cricoarytenoideus dorsalis (CADM), cricoarytenoideus lateralis (CALM), transversus arytenoideus, vocalis, and ventricularis muscles.^{11,12} Clinically, this condition manifests itself as decreased or absent arytenoid abduction and affects the left arytenoid more commonly than the right arytenoid.⁴ Denervated muscle has a characteristic ultrasonographic appearance; the muscle becomes hyperechoic to normal muscle and has a more homogeneous appearance with a loss of the normal striated pattern.¹³⁻¹⁵ These changes have been observed ultrasonographically in the CALM and CADM of horses with treadmill UA endoscopy-confirmed recurrent laryngeal neuropathy.^{8,10}

The precise etiology of arytenoid chondritis remains unclear but likely results from local trauma

NOTES

IMAGING

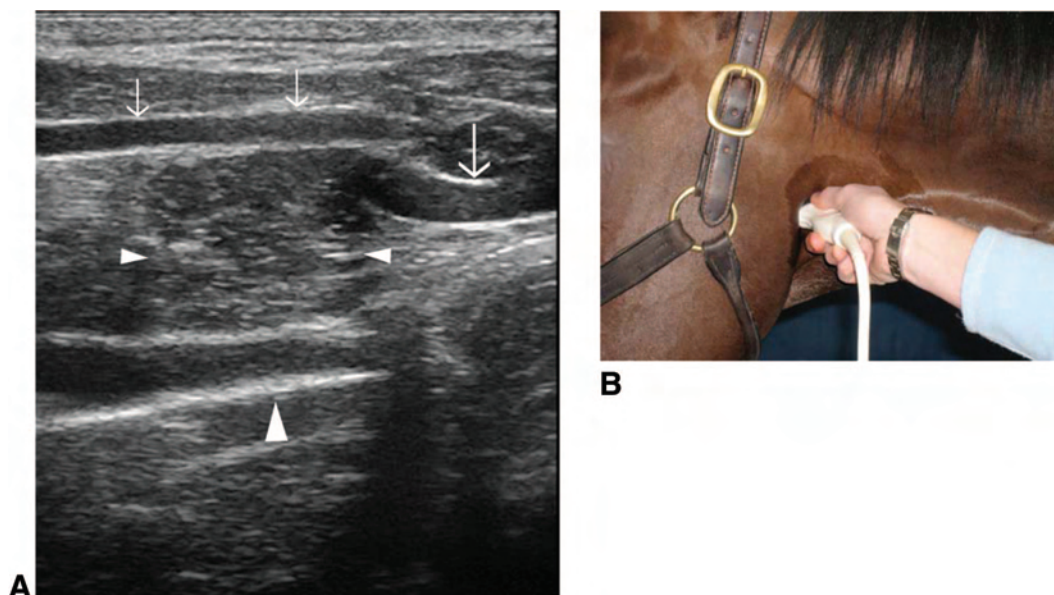


Fig. 1. Dorsal plane ultrasound image of the lateral aspect of a normal larynx (A). Transducer position is shown in B. Note the position of the cricoarytenoideus lateralis muscle (small arrowheads) between the thyroid cartilage (small arrows) and the arytenoid cartilage (large arrowhead). The cricoid cartilage (large arrow) is caudal to the thyroid cartilage. Rostral is to the left of the image and caudal is to the right of the image.

to and subsequent bacterial infection of the arytenoid cartilage.¹⁶ Some horses may have granulomas only on the axial surface of the arytenoid cartilage, whereas the pathology may progress to involve the entire arytenoid cartilage in other horses. In more severe cases, the arytenoid becomes thickened with irregular margins and has impaired movement, which may be appreciated endoscopically.¹⁷ The presence of arytenoid cartilage thickening, irregular margination, and abnormal echogenicity typical of this disease has been imaged using ultrasonography.⁷

A congenital defect known as laryngeal dysplasia (also known as fourth branchial arch defect or 4-BAD) may cause abnormal arytenoid movement of either the left or right arytenoid cartilage.^{18,19} Horses with this condition may also have constant or intermittent rostral displacement of the palatopharyngeal arch during UA endoscopy or dorsal displacement of the soft palate.^{9,20} Horses with laryngeal dysplasia have characteristic anatomic abnormalities, including lack of a cricothyroid articulation and extension of the thyroid lamina dorsal to the muscular process of the arytenoid cartilage, and they may have pharyngeal muscle abnormalities as well.^{19–21} The ultrasonographic appearance of these anatomic features has been described.⁹

The pathophysiology of DDSP has not been fully elucidated but may involve an inability to maintain a rostral position of the larynx.²² Interestingly, a change in the position of the basihyoid bone after surgical treatment (laryngeal tie-forward) is associated with an increased likelihood of racing post-operatively.²³ This finding prompted initial investigation into

an ultrasonographic marker for DDSP, which has shown that horses with DDSP had a smaller average distance between the skin and basihyoid bone than horses without DDSP.²⁴ However, the difference in this measurement between horses with and without DDSP was less than 2 mm, limiting its use in clinical situations.

The etiology of other UA disorders, including pharyngeal collapse, billowing of the soft palate, epiglottic retroversion, laryngeal collapse associated with flexed head position, and axial deviation of the aryepiglottic folds, remains unclear.^{16,25} No characteristic ultrasonographic findings of these disorders have been described.

The purpose of this paper is to provide the practitioner with instruction on how to perform a laryngeal ultrasonographic examination and incorporate this tool into his or her evaluation of the UA.

2. Materials and Methods

Horses are prepared for the examination by sedation with xylazine hydrochloride (0.4 mg/kg, IV). Most horses do not need to have the laryngeal region clipped before examination, but if the coat is coarse or thick, clipping will improve image quality. The head is held in an extended position by a handler or stand to move the laryngeal region caudally in relation to the mandible. A linear or curvilinear transducer can be used for the examination. A frequency of 8–10 MHz typically provides adequate penetration while preserving resolution.

Examination of the lateral portion of the larynx can be performed in the dorsal and transverse planes. In the dorsal plane, an initial image of the

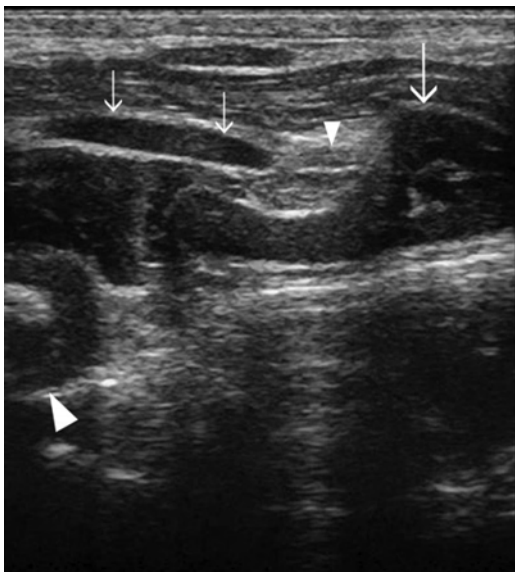


Fig. 2. Dorsal plane ultrasound image of the lateral aspect of a normal larynx. This image is slightly dorsal and caudal to Figure 1. The cricothyroid articulation (small arrowhead) is formed by the caudal cornu of the thyroid cartilage (small arrows) and the articular process of the cricoid cartilage (large arrow). The muscular process of the arytenoid cartilage is also imaged (large arrowhead). Rostral is to the left of the image and caudal is to the right of the image.

superficially positioned thyroid cartilage, the cricoid cartilage caudal to the thyroid cartilage, and the arytenoid cartilage deep to the thyroid cartilage can be obtained (Fig. 1). The CALM is imaged between the thyroid and arytenoid cartilages, and the cricothyroideus muscle is imaged between the thyroid and cricoid cartilages. By moving the transducer slightly dorsally, one can image the cricothyroid articulation, which is formed by the caudal cornu of the thyroid cartilage and the articular process of the cricoid cartilage (Fig. 2). Mineralization of the caudal cornu of the thyroid cartilage is common, but this does not seem to be clinically significant. From the cricothyroid articulation, the transducer is moved dorsally and angled slightly ventrally. In this location, one can image the cricoarytenoid articulation between the muscular process of the arytenoid cartilage and the dorsal cricoid cartilage. The lateral portion of the CADM may be evaluated as well (Fig. 3).

The lateral aspect of the larynx is also evaluated in the transverse plane. The initial image obtained is the superficially positioned thyroid lamina with the arytenoid cartilage deep to the thyroid lamina and the CALM and vocalis muscle between the thyroid and cricoid cartilages (Fig. 4). In some horses, the vocalis muscle is imaged distinctly from the CALM, but in others, the distinction between the two muscles cannot be defined. If the transducer is moved caudally, the caudal cornu of the thyroid

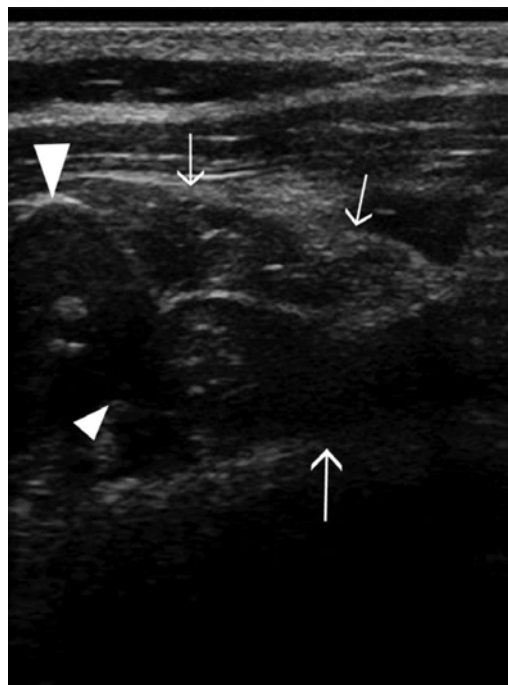


Fig. 3. Dorsal plane ultrasound image of the dorsolateral aspect of a normal larynx. This image is dorsal to Figure 1. The cricoarytenoid articulation (small arrowhead) is formed by the muscular process of the arytenoid (large arrowhead) and the dorsolateral cricoid cartilage (large arrow). The lateral portion of the cricoarytenoideus dorsalis muscle is imaged (small arrows). Rostral is to the left of the image and caudal is to the right of the image.

cartilage, the cricothyroid articulation, and the cricoid cartilage are imaged.

The ventral portion of the larynx can be examined in transverse and median planes. In a transverse plane, the tracheal rings can serve as a reference point. From the tracheal rings, as the transducer is moved rostrally, the ventral aspect of the cricoid cartilage is identified (Fig. 5), followed by the thyroid cartilage. Deep to the thyroid cartilage, the vocal folds may be imaged, and their movements can be observed (Fig. 6). The mineralized rostral aspect of the ventral thyroid cartilage is encountered next. Between the thyroid cartilage and the basihyoid bone, the thyrohyoid bones may be imaged laterally. The basihyoid bone appears as a horizontal line (Fig. 7), and if the transducer is angled rostrally from this position, the ceratohyoid bones are imaged. By moving the transducer rostrally, the lingual process of the basihyoid bone is imaged. The depth of the basihyoid bone can be measured at the junction between the lingual process and body of the basihyoid bone. In the median plane, the relationship between the lingual process and the mineralized rostral aspect of the thyroid cartilage can be evaluated. The ventral aspect of the cricoid and tracheal rings can also be imaged.

IMAGING

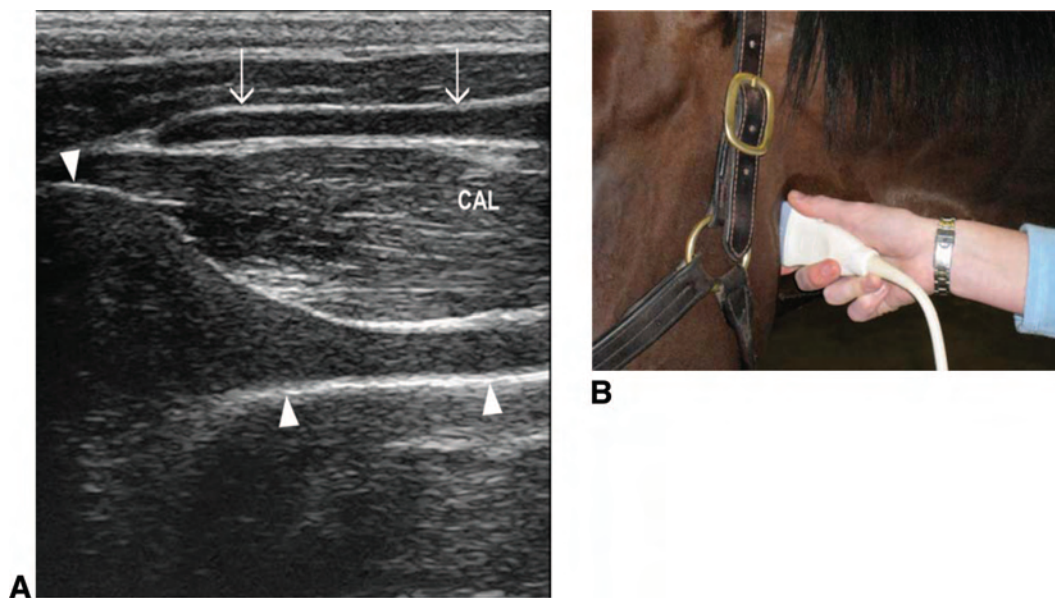


Fig. 4. Transverse plane ultrasound image of the lateral aspect of a normal larynx (A). Transducer position is shown in B. Note the position of the cricoarytenoid lateralis muscle (CAL) between the thyroid cartilage (arrows) and the arytenoid cartilage (arrowheads). The arytenoid cartilage has a trumpet bell shape and the cricoarytenoid lateralis muscle has a striated appearance with heterogeneous echogenicity. Dorsal is to the left of the image and ventral is to the right of the image.

In general, the overall symmetry of the laryngeal cartilages and associated musculature should be evaluated. The cartilages should be smoothly margined with homogeneous echogenicity, although mineralization of the thyroid and arytenoid cartilages is fairly common (Fig. 8), especially in older horses. The muscles normally have heterogeneous echogenicity and have a striated pattern in a longitudinal view.

Comparison of the relative echogenicity of the left and right CALM and CADM enables the practitioner to assess whether one structure has the hyper-echogenicity characteristic of denervation atrophy

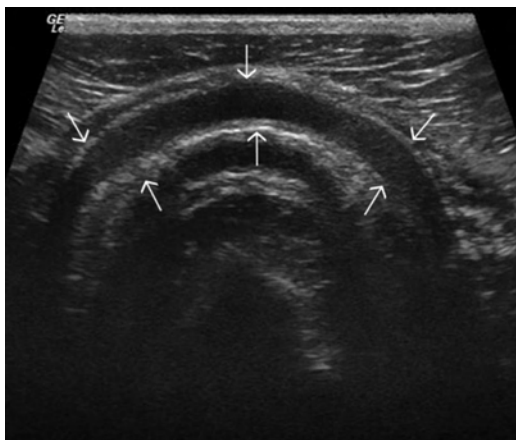


Fig. 5. Transverse plane ultrasound image of the ventral aspect of the cricoid cartilage (arrows) of a normal larynx. Left is to the left of the image and right is to the right of the image.

of recurrent laryngeal neuropathy. Ultrasound machine settings should be kept constant between left and right sides of the larynx, and images should be evaluated in dorsal and transverse planes. Side by side comparison is often useful (Fig. 9). It should be borne in mind that many factors will contribute to the ultrasonographic appearance of the muscles, and therefore, comparison within a horse is preferable to comparison between horses.

The contour of the arytenoid cartilages should be assessed critically. The arytenoid cartilages should have a trumpet bell shape with smooth margins. Horses with chondritis have irregularity of the axial and abaxial margins with thickening of the cartilage and abnormal echogenicity within the arytenoid cartilage (Fig. 10). Horses may have only a granuloma or chondroma on the axial surface of the arytenoid cartilage without diffuse arytenoid chondritis. Ultrasonographically, this manifests as focal irregularity of the axial margin, smooth abaxial margin, and normal arytenoid cartilage width.

The anatomic abnormalities characteristic of laryngeal dysplasia can also be observed. The extension of the thyroid cartilage dorsal to the muscular process of the arytenoid cartilage can best be imaged in the transverse plane (Fig. 11), whereas the lack of a cricothyroid articulation is best imaged in the dorsal plane (Fig. 12). In these horses, the relationship between the thyroid cartilage, cricoarytenoid lateralis muscle, and arytenoid cartilage is abnormal; the CALM is often positioned caudal to the thyroid cartilage in the gap between the thyroid cartilage and cricoid cartilage.

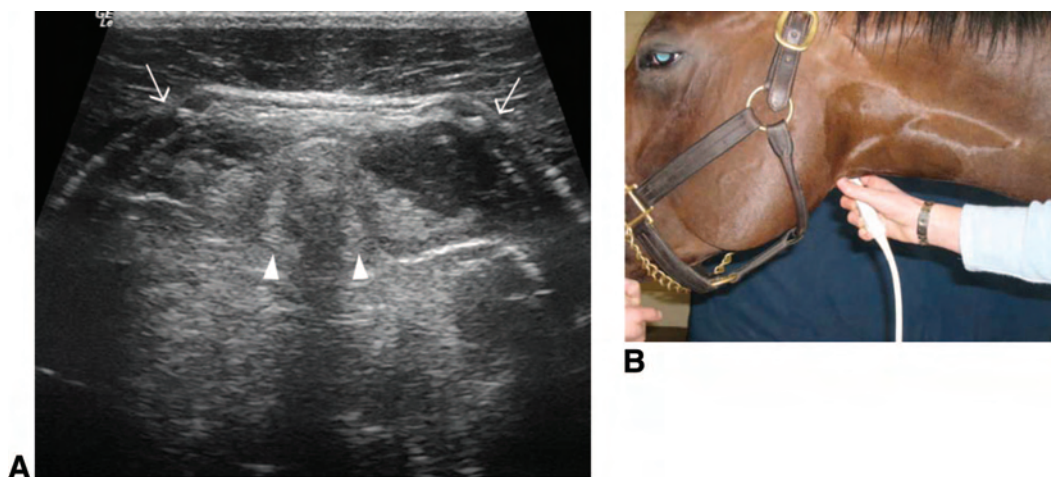


Fig. 6. Transverse plane ultrasound image (A) of the ventral aspect of the thyroid cartilage (arrows) of a normal larynx at the level of the vocal folds (arrowheads). Transducer position is shown in B. The movement of the vocal folds can be observed during respiration. Left is to the left of the image and right is to the right of the image.

Medical records of Rood and Riddle Equine Hospital were examined to identify horses that had undergone UA endoscopy (resting and/or dynamic) as well as laryngeal ultrasonography. Results of UA endoscopy and laryngeal ultrasonography as well as the final diagnosis were recorded.

3. Results

Between 2008 and 2009, 330 horses that presented to Rood and Riddle Equine Hospital for evaluation of the UA underwent laryngeal ultrasonography. A variety of breeds and uses were represented in this group. All horses underwent resting UA endoscopy, and a subset (148 horses) underwent treadmill UA endoscopy as well.

One hundred thirty-one horses were diagnosed with left recurrent laryngeal neuropathy based on results of resting and/or treadmill UA endoscopy or

previous prosthetic laryngoplasty. One hundred twenty of these horses (92%) had hyperechogenicity of the left CALM and/or CADM characteristic of muscle denervation. The remaining 11 horses had normal echogenicity of the left CALM and CADM; 4 of these 11 horses were also diagnosed with DDSP during dynamic UA examination. In the opinion of the attending clinician, DDSP was felt to be the primary cause of poor performance. Three of the eleven horses did not undergo dynamic examination, and diagnosis was made during resting UA endoscopy only.

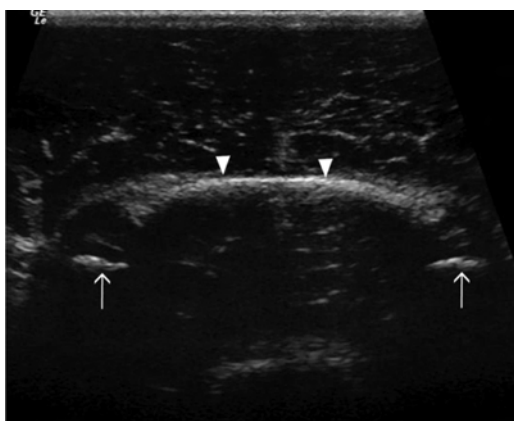


Fig. 7. Transverse plane ultrasound image of the basihyoid bone (arrowheads) and the ceratohyoid bones (arrows) of a normal larynx, obtained with the transducer positioned ventrally. Left is to the left of the image and right is to the right of the image.

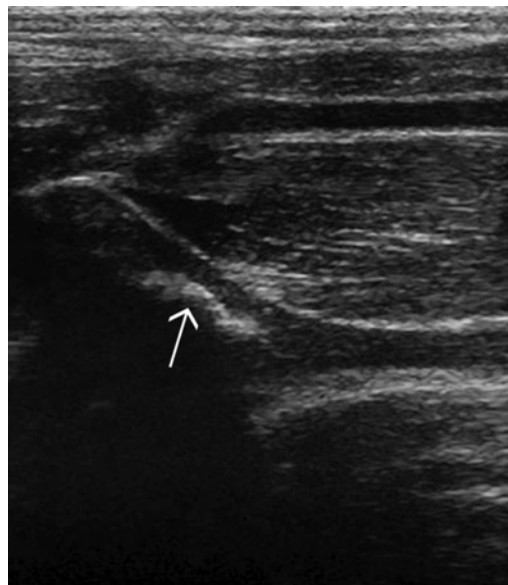


Fig. 8. Transverse plane ultrasound image of the lateral aspect of a normal larynx. Note the mineralization of the muscular process of the arytenoid cartilage (arrow). Dorsal is to the left of the image and ventral is to the right of the image.

IMAGING

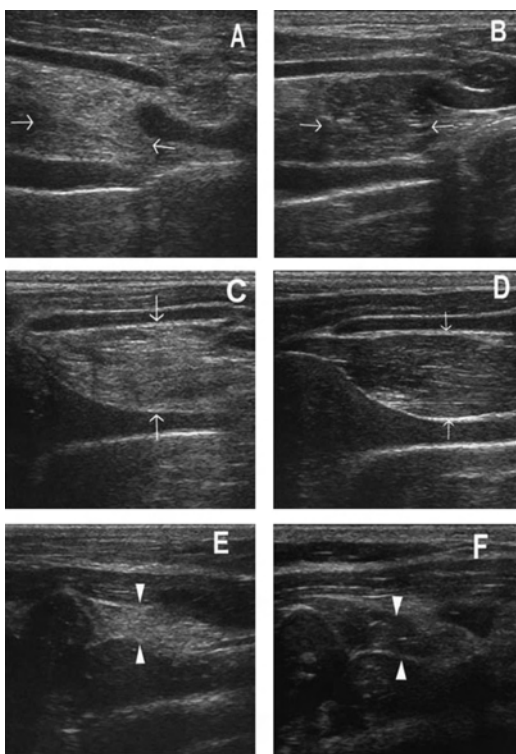


Fig. 9. Comparison of echogenicity of the cricoarytenoideus lateralis (arrows) and cricoarytenoideus dorsalis (arrowheads) musculature. Horses with recurrent laryngeal neuropathy have increased echogenicity and more homogeneous echogenicity of the cricoarytenoideus lateralis and cricoarytenoideus dorsalis muscles. Dorsal plane ultrasound images of the cricoarytenoideus dorsalis muscle of a horse with recurrent laryngeal neuropathy (A) and a normal horse (B). Transverse plane ultrasound images of the cricoarytenoideus dorsalis muscle of a horse with recurrent laryngeal neuropathy (C) and a normal horse (D). Dorsal plane ultrasound images of the cricoarytenoideus lateralis muscle of a horse with recurrent laryngeal neuropathy (E) and a normal horse (F). In the dorsal plane images, rostral is to the left and caudal is to the right and in the transverse plane images, dorsal is to the left of the image and ventral is to the right of the image.

Conversely, there were 127 horses with hyper-echogenicity of the CALM and/or CADM. One hundred twenty-two (96%) of these horses were diagnosed with recurrent laryngeal neuropathy using resting and/or dynamic UA endoscopy. The remaining five horses were diagnosed with DDSP (three horses), axial deviation of the aryepiglottic folds (one horse), and axial deviation of the vocal cords and aryepiglottic folds (one horse) during dynamic UA endoscopy.

Twenty-nine horses were diagnosed with arytenoid chondritis using resting UA endoscopy. In three of these cases, arytenoid chondritis was initially diagnosed during UA endoscopy, but ultrasonographic examination showed a normal arytenoid contour. One of these three horses was subsequently diagnosed with DDSP during a dynamic treadmill examination. An-

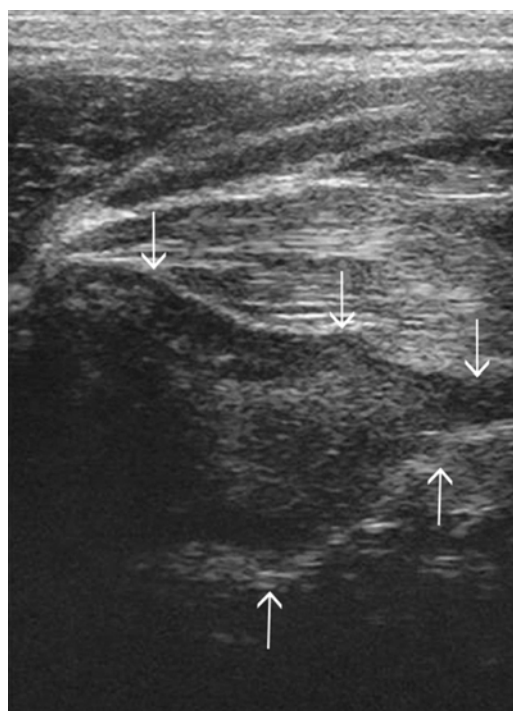


Fig. 10. Transverse plane ultrasound image of the lateral aspect of the larynx of a horse with arytenoid chondritis. The arytenoid cartilage (arrows) is severely thickened with irregular margins and increased echogenicity in its interior. Dorsal is to the left of the image and ventral is to the right of the image.

other horse had hyper-echogenicity of the CALM and was diagnosed with recurrent laryngeal neuropathy during dynamic treadmill examination. The third horse did not undergo dynamic examination but was diagnosed with DDSP based on results of resting UA endoscopy.

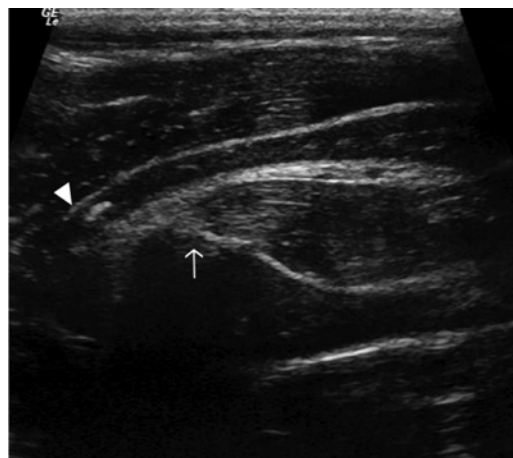

Fig. 11. Transverse plane ultrasound image of the lateral aspect of the larynx of a horse with laryngeal dysplasia. The thyroid lamina (arrowhead) extends dorsal to the muscular process of the arytenoid cartilage (arrow). Dorsal is to the left of the image and ventral is to the right of the image.

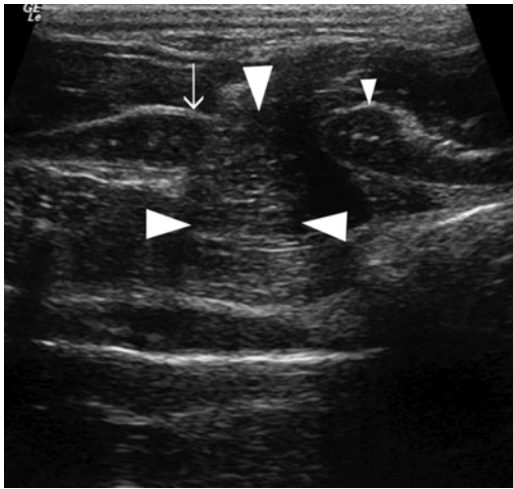


Fig. 12. Dorsal plane ultrasound image of the lateral aspect of the larynx of a horse with laryngeal dysplasia. The thyroid cartilage (arrow) and the cricoid cartilage (small arrowheads) do not articulate. The cricoarytenoideus lateralis muscle (large arrowheads) is positioned between the thyroid cartilage and cricoid cartilage in the gap between the two cartilages. Rostral is to the left of the image and caudal is to the right of the image.

Five horses were diagnosed with arytenoid granulomas or chondromas during resting UA endoscopy. In all five horses, ultrasonography revealed the mass on the axial surface of the arytenoid cartilage, and there was no evidence of arytenoid chondritis affecting the entire cartilage.

Seven horses were diagnosed with laryngeal dysplasia. In all cases, ultrasonography showed a lack of a cricothyroid articulation and extension of the thyroid cartilage dorsal to the muscular process of the arytenoid cartilage unilaterally or bilaterally. Abnormalities seen during UA endoscopy of these horses included abnormal left or right arytenoid cartilage movement, rostral displacement of the palatopharyngeal arch, and dorsal displacement of the soft palate.

Other more unusual anatomic malformations have been diagnosed in individual cases. One foal with abnormal UA noise and exercise intolerance had cyst-like structures in the thyroid, arytenoid, and cricoid cartilages as well as the first tracheal ring. An adult horse with dorsal displacement of the soft palate was found to have a basihyoid bone malformation. A Paint horse heterozygous (N/H) for hyperkalemic periodic paralysis (HYPP) had hypertrophy of the left vocalis muscle.

Seventy-five horses were diagnosed with DDSP. These horses did not have any characteristic ultrasonographic abnormalities.

All horses with normal UA endoscopic examinations had normal ultrasonographic examinations. Additionally, horses with pharyngeal collapse, billowing of the soft palate, epiglottic retroversion, laryngeal collapse associated with flexed head po-

sition, abnormal arytenoid movement secondary to thrombophlebitis, and axial deviation of the aryepiglottic folds had normal ultrasonographic examinations.

4. Discussion

Ultrasonography of the laryngeal region can be performed easily in an ambulatory or hospital setting, is a non-invasive and safe procedure, and requires no specialized equipment beyond an ultrasound machine with a linear or curvilinear transducer. Clipping of the hair is not required, and light sedation is generally sufficient to ensure patient compliance; therefore, client and patient acceptance of the procedure has been excellent.

Currently, ultrasonography of the larynx is an excellent tool for investigation of the reason for abnormal arytenoid movement, because the cause may be difficult to determine with resting UA endoscopy alone. Evidence of hyperechogenicity of the left CALM and CADM would support a diagnosis of left recurrent laryngeal neuropathy as a cause of poor performance or abnormal UA noise. In cases of arytenoid chondritis, ultrasonography permits imaging of nearly the entire arytenoid cartilage. This has allowed us to assess the extent of disease in the cartilage, diagnose any associated abscesses or perilaryngeal inflammation, and monitor response to treatment. In some of the cases in this report, the ultrasonographic findings did not support a diagnosis of arytenoid chondritis, leading to additional investigation and revision of the diagnosis. Congenital abnormalities involving the laryngeal cartilages can be imaged directly instead of being inferred from UA endoscopic abnormalities.

Although previous work²⁴ has shown a small (<2 mm) difference in the depth of the basihyoid bone between horses with and without DDSP, no significant difference was identified between these groups in our population. No abnormal ultrasonographic findings were observed for a group of conditions of the UA (pharyngeal collapse, billowing of the soft palate, epiglottic retroversion, and axial deviation of the aryepiglottic folds), but further work may reveal characteristic findings in these diseases.

In our practice, ultrasonography of the larynx has been incorporated as a routine procedure for investigation of UA disorders, because it contributes to a more thorough evaluation of the UA. Endoscopy is an excellent tool for assessment of laryngeal function and abnormalities visible at the luminal aspect of the larynx, but ultrasonography allows more complete examination of the laryngeal cartilages and associated musculature, structures that were previously difficult to evaluate. Additionally, ultrasonography can be useful in evaluation of poor performance or abnormal UA noise in cases where a dynamic UA examination is not feasible (because of availability, financial or liability concerns, concu-

IMAGING

rent lameness, or other factors). Hopefully, future work will expand the uses of laryngeal ultrasonography for a variety of UA conditions.

References

- Martin BB, Davidson EJ, Durando MM, et al. Clinical exercise testing: overview of causes of poor performance. In: Hinchcliff KW, Kaneps AJ, Geor RJ, et al., eds. *Equine sports medicine and surgery*. Edinburgh: Saunders, 2004;32–41.
- Martin BB Jr., Reef VB, Parente EJ, et al. Causes of poor performance of horses during training, racing, or showing: 348 cases (1992–1996). *J Am Vet Med Assoc* 2000;216:554–558.
- Morris EA, Seeherman HJ. Clinical evaluation of poor performance in the racehorse: the results of 275 evaluations. *Equine Vet J* 1991;23:169–174.
- Anonymous. Workshop summary consensus statements on equine recurrent laryngeal neuropathy, in *Proceedings. Havemeyer Foundation Workshop on Equine Recurrent Laryngeal Neuropathy* 2003;93–97.
- Desmaizieres LM, Serraud N, Plainfosse B, et al. Dynamic respiratory endoscopy without treadmill in 68 performance Standardbred, Thoroughbred and saddle horses under natural training conditions. *Equine Vet J* 2009;41:347–352.
- Rakestraw PC, Hackett RP, Ducharme NG, et al. Arytenoid cartilage movement in resting and exercising horses. *Vet Surg* 1991;20:122–127.
- Chalmers HJ, Cheetham J, Yeager AE, et al. Ultrasonography of the equine larynx. *Vet Radiol Ultrasound* 2006;47:476–481.
- Chalmers HJ, Cheetham J, Mohammed HO, et al. Ultrasonography as an aid in the diagnosis of recurrent laryngeal neuropathy in horses, in *Proceedings. 16th American College of Veterinary Surgeons Symposium* 2006;3–4.
- Garrett KS, Woodie JB, Embertson RM, et al. Diagnosis of laryngeal dysplasia in five horses using magnetic resonance imaging and ultrasonography. *Equine Vet J* 2009;41:766–771.
- Garrett KS, Woodie JB, Embertson RM. Association of treadmill upper airway endoscopic evaluation of arytenoid movement with results of laryngeal ultrasonography and resting upper airway endoscopic evaluation for diagnosis of recurrent laryngeal neuropathy in Thoroughbred racehorses. *Equine Vet J*, submitted.
- Duncan ID, Amundson J, Cuddon PA, et al. Preferential denervation of the adductor muscles of the equine larynx. I. Muscle pathology. *Equine Vet J* 1991;23:94–98.
- Duncan ID, Reifenrath P, Jackson KF, et al. Preferential denervation of the adductor muscles of the equine larynx. II. Nerve pathology. *Equine Vet J* 1991;23:99–103.
- Gunreben G, Bogdahn U. Real-time sonography of acute and chronic muscle denervation. *Muscle Nerve* 1991;14:654–664.
- Kullmer K, Sievers KW, Reimers CD, et al. Changes of sonographic, magnetic resonance tomographic, electromyographic, and histopathologic findings within a 2-month period of examinations after experimental muscle denervation. *Arch Orthop Trauma Surg* 1998;117:228–234.
- Walker FO. Neuromuscular ultrasound. *Neurol Clin* 2004;22:563–590.
- Holcombe SJ, Ducharme NG. Abnormalities of the upper airway. In: Hinchcliff KW, Kaneps AJ, Geor RJ, et al., eds. *Equine sports medicine and surgery*. Edinburgh: Saunders, 2004;559–598.
- Haynes PF, Snider TG, McClure JR, et al. Chronic chondritis of the equine arytenoid cartilage. *J Am Vet Med Assoc* 1980;177:1135–1142.
- Kannegieter NJ, Goulden BE, Anderson LJ. Right-sided laryngeal dysfunction in a horse. *New Zeal Vet J* 1986;34:66–68.
- Lane JG. Fourth branchial arch defects in Thoroughbred horses: a review of 60 cases, in *Proceedings. 2nd World Equine Airways Symposium* 2001. Available at <http://www.ivis.org/proceedings/weas/2001/Lane.pdf>. Accessed on January 21, 2010.
- Goulden BE, Anderson LJ, Davies AS, et al. Rostral displacement of the palatopharyngeal arch: a case report. *Equine Vet J* 1976;8:95–98.
- Dixon PM, McGorum BC, Else RW. Cricopharyngeal-laryngeal dysplasia in a horse with sudden clinical onset idiopathic laryngeal hemiparesis. *New Zeal Vet J* 1993;41:134–138.
- Ducharme NG, Hackett RP, Woodie JB, et al. Investigations into the role of the thyrohyoid muscles in the pathogenesis of dorsal displacement of the soft palate in horses. *Equine Vet J* 2003;35:258–263.
- Cheetham J, Pigott JH, Thorson LM, et al. Racing performance following the laryngeal tie-forward procedure: a case-controlled study. *Equine Vet J* 2008;40:501–507.
- Chalmers HJ, Yeager AE, Ducharme N. Ultrasonographic assessment of laryngochoyoid position as a predictor of dorsal displacement of the soft palate in horses. *Vet Radiol Ultrasound* 2009;50:91–96.
- Strand E, Fjordbakk CT, Holcombe SJ, et al. Effect of poll flexion and dynamic laryngeal collapse on tracheal pressure in Norwegian Coldblooded Trotter racehorses. *Equine Vet J* 2009;41:59–64.